

Different Tissue Responses for Iodine and Iodide in Rat Thyroid and Mammary Glands

BERNARD A. ESKIN,^{*1} CAROLYN E. GROTKOWSKI,²
CHRISTOPHER P. CONNOLLY,¹ AND WILLIAM R. GHENT³

¹Department of Obstetrics and Gynecology, Medical College
of Pennsylvania, Philadelphia, PA 19129; ²Department
of Pathology, Medical College of Pennsylvania, Philadelphia, PA;
and ³Department of Surgery, Queen's University, Kingston,
Ontario, Canada

Received July 27, 1994; Accepted August 8, 1994

ABSTRACT

This research describes the effects of short-term elemental iodine (I_2) and iodide (I^-) replacement on thyroid glands and mammary glands of iodine-deficient (ID) Sprague-Dawley female rats. Iodine deficiency causes atypical tissue and physiologic changes in both glands. Tissue histopathology and the endocrine metabolic parameters, such as serum TT_4 , tissue and body weights, and vaginal smears, are compared. A moderate reduction in thyroid size from the ID control (IDC) was noted with both I^- and I_2 , whereas serum total thyroxine approached the normal control with both I^- and I_2 , but was lower in IDC. Thyroid gland IDC hyperplasia was reduced modestly with I_2 , but eliminated with I^- . Lobular hyperplasia of the mammary glands decreased with I_2 and increased with I^- when compared with the IDC; extraductal secretions remained the same as IDC with I_2 , but increased with I^- ; and periductal fibrosis was markedly reduced with I_2 , but remained severe with I^- . Thus, orally administered I_2 or I^- in trace doses with similar iodine availability caused different histopathological and endocrine patterns in thyroid and mammary glands of ID rats. The significance of this is that replacement therapy with various forms of iodine are tissue-specific.

Index Entries: Iodine; iodide; thyroid gland; mammary glands; rats; iodine deficiency.

*Author to whom all correspondence and reprint requests should be addressed.

INTRODUCTION

The mechanisms by which all forms of iodine act in most tissues had been considered to be similar to the iodine pathway established in the thyroid gland (1,2). However, elemental iodine (I_2) and iodide (I^-) have been seen to distribute differently in iodine-receptive tissues, such as stomach, blood, liver, thyroid, and gastrointestinal tract, which indicates that alternative biochemical pathways may exist (3,4). The female mammary gland is another organ that shows considerable iodine presence and metabolism particularly during pregnancy, nursing, and active estrogen stimulation (5-8).

The thyroid gland histopathology resulting from iodine deficiency states has been well documented (2). The cellular atypias described in the mammary glands with iodine deprivation appear to be also readily recognizable (5,9-12) and may resemble the benign fibrocystic breast disease seen in women (13,14). The effects of iodine replacement may be dependent on the form given and the tissues observed. For this reason, two major types of iodine, elemental I_2 and I^- , were used in this *in vivo* study, and the effects of these substances on rat thyroid and mammary glands were compared.

MATERIALS AND METHODS

Forty-four Sprague-Dawley albino virgin female rats weighing 204-224 g initially were used. All rats except the normal diet controls (Group I) were fed Remington iodine-deficient diet #170360 (Teklad, Madison, WI) for 2 wk.

Perchlorate-treated water was given *ad lib* for the first 4 d in order to release further stored iodine in the affected tissues. A low-iodine state would enable the two forms of iodine (I_2 and I^-) to be biologically observed in an almost iodine-free model. Estrogen was injected every other day to maintain estrus in the rat. This results in stimulated breast tissues, which can be more easily compared histologically.

Group I consisted of 10 rats. These sham-treated rats were given a normal Purina Rat Chow diet and double-distilled water.

Group II, the iodine-deficient control group, consisted of 10 rats. These rats were given the Remington diet for 2 wk, perchlorate-treated water for the first 4 d, and estrogen injections every other day.

Group III consisted of 16 rats. They received the Remington diet for 2 wk, perchlorate-treated water for the first 4 d, and estrogen injections every other day. In addition, Group III was also given I_2 for the last 10 d of the experiment.

Group IV was composed of eight rats. This group was given the Remington diet for 2 wk, perchlorate-treated water for the first 4 d, and estrogen injections every other day. Additionally, Group IV was treated with potassium iodide for the last 10 d of the experiment.

Perchlorate treatment consisted of 400 mg/100 mL sodium perchlorate in deionized, distilled water for the first 4 d. The estradiol dose was designed to maintain a persistent estrus, thus promoting active mammary glands. Estrogen treatment consisted of im injections administered as 2.5 μg of estradiol 17- β in 100 μL of sesame oil every other day for the entire 2 wk. Vaginal smears were taken every other day, which showed that the rats achieved constant estrus throughout the experiment.

I₂ therapy consisted of 80 μg of molecular iodine/100 mL of double-distilled drinking water. Each rat consumed about 25 mL/d. Therefore, the dosage for each rat was 20 $\mu\text{g}/\text{d}$, or 80 $\mu\text{g}/\text{kg}$ body wt. I⁻ therapy consisted of 120 μg of potassium iodide (KI)/100 mL of double-distilled drinking water. Thus, the dosage for each of these rats was 30 $\mu\text{g}/\text{d}$ or 120 $\mu\text{g}/\text{kg}$ body wt of I⁻.

I₂ was delivered to the rats in foil-covered 100-mL bottles with short spouts changed twice daily with maximal air space of 12.5 mL. Sublimation was small and calculated to be <10%. Total volatility loss because of reduced vapor pressure was measured at 30%.

The doses used were calculated on the basis of molar iodine. KI given was 120 μg or a concentration of 0.92 μmol of iodine, whereas molecular I₂ was given as 80 μg or 1.60 μmol of iodine. After accounting for the physical losses (40%), this would be 0.96 μmol . Intake of the treated water by both groups was the same. Thus, the iodine availabilities of the aqueous I₂ and KI (I⁻) solutions given to the rats were similar. A dose-response clinical evaluation provided the level of iodine (molar iodine) that significantly reduced fibrocystic disease in breast tissues. This dose approximated the therapeutic level for clinical studies (14).

The rats were weighed initially and then daily. At the end of the 2-wk study, the rats were killed by carbon dioxide. The six lower mammary glands bilaterally and the thyroid glands were dissected free and fixed in a 10% formalin solution. Ovaries, adrenal, and thyroid glands were weighed. Venous blood was removed from the inferior vena cava, centrifuged, and the collected serum was frozen. Total serum thyroxine (TT₄) was measured for all rats using a solid-phase ¹²⁵I TT₄ RIA kit (DPC, Los Angeles, CA). Microscopic sections of the thyroid and mammary gland tissues were stained with hematoxylin and eosin. All slides were coded and graded by a pathologist.

All rat studies were conducted in accordance with the highest standards of humane animal care as outlined in the *NIH Guide for the Care and Use of Laboratory Animals*.

RESULTS

Weights (Table 1)

Initial and final body weights were taken and compared. The short growth patterns seen in 2 wk were within the normal limits for the strain used, and no statistical differences were noted. Although a statistical dif-

Table 1
Mean Body, Adrenal, and Ovarian Weights

Group	n	Initial body, g	Final body, g	Adrenal, mg/kg	Ovaries ^a , mg/kg
I Normal diet	10	204 ± 3	239 ± 5	155.0 ± 11.2	473.6 ± 23.7
II Iodine deficient no treatment	10	206 ± 4	226 ± 5	196.5 ± 15.8	526.8 ± 27.5
III Iodine deficient iodine (I ₂)	16	219 ± 4	240 ± 6	176.0 ± 16.6	534.6 ± 22.3
IV Iodine deficient Iodide (I ⁻)	8	224 ± 7	231 ± 3	181.9 ± 10.6	582.6 ± 32.7

Weights expressed as mean weights ± SEM. All statistics were calculated using the Dunnett *t*-test (Statview-Macintosh).

^aOvarian weight: Group I vs. Group II *p* < .05, Group I vs. Group III *p* < .01, and Group I vs. Group IV *p* < .01.

ference (*p* < 0.01) between the adrenal weights of the normal diet and the iodine-deficient untreated groups were seen, they remained within normal levels. Ovarian weight, on the other hand, was significantly higher in all the estrogen-treated animals as expected.

Thyroid Weights and Function (Table 2)

The thyroid weights increased from normal controls, as anticipated, in all untreated iodine-deficient rats; however, both iodine therapies caused significant reductions. Total serum thyroxine was within the expected range of the kit in all four groups (3.1–6.2 µg/dL). However, the treatment groups differed significantly. Both iodine treatments increased the level of serum thyroxine, whereas the I⁻ treatment group appeared to be closer than the I₂ group to the normal control median.

Mammary Gland Histology

All slides were coded and read blindly by one pathologist, and then reviewed by all authors for discussion and concordance diagnosis. All scoring was done without knowledge of the source of the sections. The method of evaluation for the histologic features was subjective and included the following criteria.

Cystic changes were scored according to size in comparison to normal lumen diameter: mild dilatation of 1.5–2 times normal (+), approx 3 times normal (++) , and >3 times normal diameter (+++). However, cystic change was not prominent, and large cyst formation (+++) was only rarely seen. Cystic change was also evaluated concerning whether lobules or ducts were involved and whether involvement was isolated or diffuse. Cystic change was not associated with metaplasia of lining cells;

Table 2
Thyroid Weight and Serum Thyroxine

Group	n	Thyroid ^a mg/kg	Total thyroxine ^b μg/dL
I Normal diet	10	98.0 ± 3.3	6.1 ± 0.5
II Iodine deficient no treatment	10	184.2 ± 6.4	3.2 ± 0.2
III Iodine deficient iodine (I ₂)	16	124.7 ± 5.5	4.8 ± 0.4
IV Iodine deficient Iodide (I ⁻)	8	122.1 ± 5.7	5.9 ± 0.4

Weights expressed as mean weights/kg ± SEM. All statistics were calculated using the Dunnett t-test (Statview-Macintosh).

^aThyroid weight, Group I vs Group II $p < .005$, Group I vs Group III $p < .01$, Group I vs Group IV $p < .01$, Group II vs Group III $p < .005$, and Group II vs Group IV $p < .005$.

^bTotal thyroxine RIA: Group I vs Group II $p < .01$, Group II vs Group III $p < .01$, Group II vs Group IV $p < .01$, and Group III vs Group IV $p < 0.02$.

only rarely were macrophages seen in dilated ducts. Epithelial changes, such as papillomatosis, papillary, or atypical hyperplasia, were not seen.

Features that were used to grade the mammary gland changes were lobular hyperplasia, secretions, periductal fibrosis, and fibroadenomatous change (Table 3).

Definite differences in the number and crowding of lobules within groups were noted. Differences in the number of lobules according to location of the mammary glands (thoracic vs abdominal glands) have been reported (15); to control for these differences, the glands were dissected and examined. The number of lobules surrounding a terminal duct was approximated and compared with an expected normal number of 1-3 lobules/terminal duct. The following general criteria were used: 3-5 lobules (+), 6-8 (++), 8-10 (+++), >10 (++++). In general, the increase was diffuse and involved the majority of terminal ducts.

Secretions appeared as basophilic material in both lobules and ducts. When this change was prominent, the basophilic material was associated with a vacuolated cytoplasm, especially in the lobules. Although the nature of the material was not further characterized, it was presumed to be normal secretory material and reflected the activity of the breast lobules.

Most notable was the amount and type of fibrosis seen (Fig. 1D, E, and F). The amount of collective tissue varied from fine reticular support structures to dense eosinophilic thick areas of fibrosis. The degree of fibrosis varied in distribution from involving only large ducts to also surrounding and encasing lobules. The following general criteria were used:

Table 3
Histologic Grading of Mammary Gland Tissue

Group	Lobular hyperplasia, $\geq++$		Secretion, $\geq++$		Periductal fibrosis, $\geq++$		Fibroadenomata	
	Ratio	%	Ratio	%	Ratio	%	Ratio	%
I Normal Diet	0/10	0	0/10	0	0/10	0	0/10	0
II Iodine deficient no treatment	3/10	30	2/10	20	9/10	90	2/10	20
III Iodine (I_2)	3/16	19	4/16	25	5/16	31	1/16	6
IV Iodine deficient Iodide (I^-)	4/8	50	4/8	50	6/8	75	4/8	50

Ratios indicate number of animals showing moderate to severe conditions over the total number of animals observed.

- + Fibrosis surrounding ducts and approx 1/2 lumen diameter in thickness;
- ++ Thickness of fibrosis similar to above, but focally involved lobules;
- +++ Fibrosis approximately equal to or greater than lumen diameter; and
- ++++ Thickness similar to above, but lobules encased in areas of fibrosis.

Occasionally, small microscopic fibroadenomas similar in morphology to human fibroadenomas were seen. These were not identified grossly and measured approx 2-3 mm.

Specifically, untreated (Group I) rats demonstrated normal histology (Table 3). Iodine-deficient untreated rats (Group II) showed lobular hyperplasia, which decreased when I_2 was used, but with I^- , the hyperplasia increased. Secretions remained the same with I_2 and iodine-deficient controls; however, secretions increased with I^- . Periductal fibrosis was markedly reduced with I_2 as compared to the iodine-deficient rats (Group II). On the other hand, periductal fibrosis remained severe with I^- treatment. Fifty percent of the I^- -treated rats had fibroadenomas present, whereas only 20% of the iodine-deficient controls and 6% of I_2 -treated animals showed this change.

Thyroid Gland Histology

The thyroid gland was bivalved and embedded; sections that were evaluated, therefore, were from the mid-most portion of the gland. Given the small size in the rat (5-10 mm), this level was approximated as best

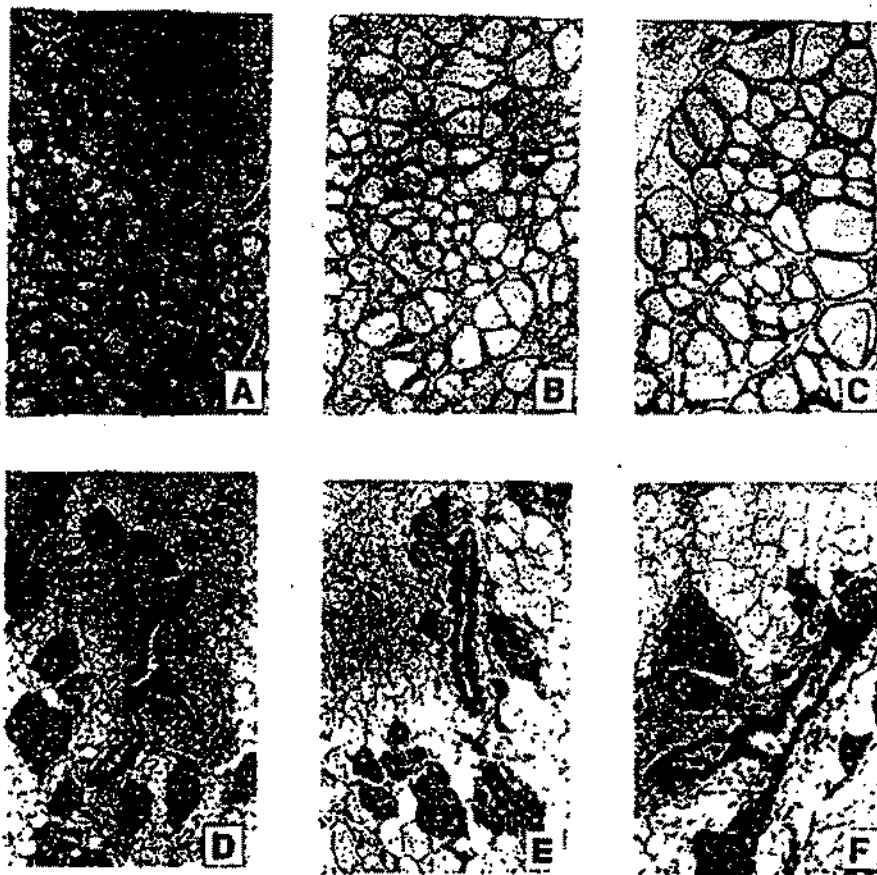


Fig. 1. Differential response in rat thyroid tissue (A-C): A. Thyroid iodine deficient (Group II): Note the small size of the follicles lined by tall active epithelium. Colloid is absent in some of the very small follicles ($\times 63$). B. Thyroid iodine treatment (Group III): Although the follicles approach more normal size and variation, small follicles still persist. Scalloping of colloid is noted in the smaller follicles in the center ($\times 63$). C. Thyroid iodide treatment (Group IV): The thyroid exhibits relatively normal appearance with larger follicles, which vary in size. The follicles are lined by more attenuated epithelium. ($\times 63$). Differential response in rat mammary tissues (D-F): D. Mammary iodine deficient (Group II): Note the prominent periductal fibrosis with dense connective tissue surrounding the large duct in the center. Focally, the width of the fibrosis is four to five times the width of the lumen and extends to the lobules. The lobules are hypercellular with as many as 15-20 lobules in crowded groups. Secretions are noted in both lobules and the large duct ($\times 63$). E. Mammary iodine treatment (Group III): The mammary tissue exhibits relatively normal histology ($\times 125$). F. Mammary iodide treatment (Group IV): Note the reduction in periductal fibrosis compared to the control group, but increased in comparison to the iodine-treated group. Some crowding and hypercellularity are seen in the lobule. Secretions are prominent within lobules and the duct ($\times 125$).

Table 4
Histologic Grading of Thyroid Tissue

	Group	Follicle Size	Colloid	Hyperplasia	Adenoma
I	Normal diet	+++	+++	0/10	0/10
	Iodine deficient	+	+	6/10	2/10
II	no treatment				
III	Iodine deficient iodine (I ₂)	++	++	0/16	2/16
IV	Iodine deficient Iodide (I ⁻)	+++	+++	0/8	4/8

Proportions indicate number of animals with condition present over total number of animals observed. Grading of follicle size and colloid is based on size as projected: + small, ++ medium, +++ large.

as possible. For an approximation in follicle size, an estimate of the number of follicles per high power field was used, so that fewer large follicles were seen than small follicles per high power field.

For assessing histologic changes in thyroid tissue, follicle size, colloid, epithelial hyperplasia, including presence of "scalloping" of colloid, and adenoma formation were compared with the normal, untreated controls (Table 4). Only rarely was papillary hyperplasia of the epithelium noted. A definite increase in the size of cells with an abundant cytoplasm was seen in the iodine-deficient group. Small follicles associated with scalloping and the enlargement of the epithelial cells were characterized as a hyperplastic change.

Thyroid hyperplasia seen in iodine deficiency cleared with either therapy (Fig. 1A, B, and C). Solitary adenomas were seen in the iodine-deficient rats and with both I⁻ and I₂. These were characterized by a proliferation of smaller more spindle-shaped cells, without a true capsule. Most impressively, follicles were small in iodine deficiency, somewhat larger with I₂, and largest with I⁻.

DISCUSSION

The major purpose of this research is to show that when rats are iodine deficient, resulting histopathology and metabolism respond differently to the replacement with trace iodine relative to the form of iodine given and the particular tissues examined. Specifically, the effects of I⁻ and elemental I₂ were observed in the mammary glands and thyroid gland. The rats involved were made iodine deficient, resulting in thyroid and mammary gland characteristics that had been described previously (5,9-12). The results of our study confirm in theory the findings of Thrall and Bull (3), who used radioactive iodine uptakes and con-

cluded that iodine distribution in the blood, stomach, skin, and thyroid glands depended on the chemical form of iodine employed for replacement. They also showed that I_2 is not reduced to I^- in the blood before it is absorbed systemically from the gastrointestinal tract (4).

The thyroid gland was compared because of its importance in iodine uptake and release. The biochemical pathway for iodine ascribed to the thyroid gland has been applied persistently to all other iodine-receptive tissues, although it appears from this study that other mechanisms may exist. I^- appears more efficient than I_2 in restoring the thyroid gland to normal from the goitrous state found in iodine deficiency when evaluated histologically and chemically.

The histology described for the mammary glands is particularly significant. Iodine deficiency has been shown to alter the structure and function of the mammary glands of rats, especially the alveolar cells (5,9,11,13). When stimulated by estrogen, either physiologically or externally, the mammary glands, particularly the alveoli, appear to be highly sensitive (8,9,11). Reasonably, the dysplasia and atypia caused by iodine deficiency in the mammary glands would be expected to reverse with iodine replacement. However, these abnormal changes are most evidently reduced when elemental I_2 is given. I_2 is distinctly more effective in diminishing the ductal hyperplasias and perilobular fibrosis in the mammary glands than I^- , using the same total iodine dose in both treatments.

Rationale for these findings must lie with the distribution and the mechanisms of action of the iodines in the specific tissues. Distribution studies with iodides and iodine have shown that there are significant differences between the uptakes measured in the thyroid, stomach, salivary glands, skin, and other iodine-affected sites (3,9). The iodine administered to the rat was the same, but differences in metabolic and histopathologic responses occurred owing to the chemical action of the singular iodines. Both forms were seen in the tissues probably transported by the blood, since I_2 was not reduced to I^- as previously thought (4). In our study, I_2 replacement was more effective than I^- on decreasing the mammary gland pathology.

Iodine mechanisms of action seen in the thyroid have been diligently investigated (2). However, only fragmented research has been available concerning extrathyroidal iodine pathways. Monoiodothyronine and diiodothyronine are described in mammary gland tissues (8,16-18). Evidence of these iodine moieties indicates the presence of a mammary gland iodine metabolism (1,6,19). Clur has hypothesized a chemical sequence whereby iodine and a tyrosyl residue in the hydrophobic estrogen binding site of the estrogen receptor are posttranslationally modified to monoiodotyrosine and, hence, 3,3' diiodothyronine monoamine (T_2) by peroxidase activity. Since estrogen receptor density is increased in iodine deficiency, the amplified effect of high-circulation estrogen plus inadequate iodine may result in the dysplastic cellular responses seen in the mammary gland tissues (20).

There are other metabolic sequences that might be considered in this query. Peroxidase is required to convert I⁻ to elemental I₂ for organification in the iodine pathway of the thyroid gland (2). Mammary glands have modest amounts of peroxidase, whereas the thyroid has abundant quantities (21). Hypothetically, replacement with I₂ would require far less peroxidase in the mammary gland iodine pathway. I₂ replacement is more efficient and would require less iodine to reduce the local iodine deficiency.

The results of this research reflect the uniqueness of replacement iodine therapy. Iodine deficiency may affect all iodine-receptive tissues, but the form of iodine required for effective replacement seems to be tissue-specific. Therapy for mammary gland atypia when iodine is lacking is particularly important, because it has potential clinical use (14). The mechanisms of iodine action in all the affected tissues need further clarification.

ACKNOWLEDGMENTS

The authors would like to thank S. Arnold and A. Griffin for their skillful technical assistance.

REFERENCES

1. N. Freinkel and S. H. Ingbar, *Endocrinology* 58, 51 (1956).
2. R-D. Hesch and J. Koehle, in Werner's *The Thyroid*, 5th ed. S. H. Ingbar and L. E. Braverman, eds., Lippincott, Philadelphia, pp. 154-200 (1986).
3. K. D. Thrall and R. J. Bull, *Fundam. Appl. Toxicol.* 15(1), 75-81 (1990).
4. K. D. Thrall, R. J. Bull, and R. L. Sauer, *J. Toxicol. Environ. Health* 37, 443-449 (1992).
5. B. A. Eskin, *Trans. NY Acad. Sci.* 32, 911-947 (1970).
6. J. M. Strum, *Anat. Rec.* 192, 235-244 (1978).
7. B. A. Eskin, C. E. Sparks, and B. I. LaMont, *Biol. Trace Element Res.* 1, 101 (1979).
8. N. M. Shah, B. A. Eskin, T. B. Krouse, and C. E. Sparks, *Proc. Soc. Exp. Biol.* 181, 443 (1986).
9. B. A. Eskin, R. Shuman, T. Krouse, and J. Merion, *CA Res.* 35, 2332 (1975).
10. T. B. Krouse, B. A. Eskin, and J. Mobini, *Arch. Pathol. Lab. Med.* 103, 631-634 (1979).
11. J. M. Strum, *Virchows Archiv-B-Cell Pathol.* 30(2), 209-220 (1979).
12. B. A. Eskin, T. B. Krouse, P. R. Modhera, and M. A. Mitchell, in *Frontiers in Thyroidology*, vol. 1, G. Medeiros-Neto and E. Gaitan, eds, Plenum, New York, p. 1027 (1986).
13. T. L. Aquino and B. A. Eskin, *Arch. Pathol.* 94, 280 (1972).
14. W. R. Ghent, B. A. Eskin, D. A. Low, and L. P. Hill, *Can. J. Surg.* 36(5), 453-460 (1993).
15. J. Russo, B. A. Gusterson, A. E. Rogers, I. Russo, S. R. Wellings, and M. J. vanZwufel, *Lab. Invest.* 62, 244 (1990).

16. G. D. Potter, W. Tong, and I. L. Chaikoff, *J. Biol. Chem.* 234, 350-354 (1959).
17. B. K. Vonderhaar and A. E. Greco, *Endocrinology* 104(2), 409 (1979).
18. J. M. Strum, P. C. Phelps, and M. M. McAtee, *J. Ultrastruct. Res.* 84, 130-139 (1983).
19. K. Brown-Grant, *J. Physiol.* 135, 644 (1957).
20. A. Clur, *Med. Hyp.* 27, 303-311 (1988).
21. E. R. DeSombre and R. C. Lytle, *CA Res.* 38, 4086-4090 (1978).